

The Role of Color Doppler Ultrasonography in the Prevention of Thromboembolic Disease after Total Hip Replacement

Hadi Farhat¹, Prof. Dr. PhD. Fadi Abdel Sater², Edwin Parra Prada³, Prof. Dr. Khodor Haidar Hasan⁴

¹University of balamand .faculty of medicine.beirut.lebanon.

²Lebanese University, faculty of science, department of biology-hadat-lebanon.

³Md. Rheumatology .rheumatology department, ospedale sandonato. Arezzo italy

⁴Md, phd.lebanese university.faculty of public health. Department of physical therapy.hadat.lebanon

ABSTRACT

Orthopedic and trauma surgery carries a high risk of deep vein thrombosis (DVT) in the lower limbs and acute pulmonary embolism (APE). In traumatology, the greatest risk is in hip fractures of the proximal extremity of the femur, especially those of the neck, and intertrochanteric fractures. In orthopedics the risk of thromboembolic complications (TEC) is particularly high in hip and knee surgery, especially in prosthetic replacement, as general factors are associated with local factors such as trauma to vessels and / or blood stasis which further aggravate the perioperative imbalance of the coagulation system. In particular, hip replacement surgery is the one that shows a higher frequency of DVT (especially affecting the proximal large vessels), and of TEC, so much so that pulmonary embolism is one of the main causes of death after this intervention. In this paper, we review the different instruments used for the diagnosis of DVT such as phlebography, radiolabeled fibrinogen collection test, impedance, plethysmography, ultrasound, nuclear magnetic resonance and computed tomography. We also discuss the different prophylaxis methods for DVT and subsequent PE prevention. Then, we performed an experimental study on 420 patient's operated on for total hip replacement at the 1st Orthopedic Clinic of the University of Florence and other private clinics in the period between 1994-1996. These are 286 first cemented implants, 36 first hybrid implants, 38 first cementless implants and 60 hip replacement reviews. This study showed the importance of color doppler ultrasonography in the prevention of DVT in hip replacement patients and subsequent APE prophylaxis. Significant relationship was found between APE and the protocole used to follow up with the patients (Pvalue 0.0007). Patients in group 2 in which only clinical control (no preoperative color doppler ultrasonography assessment) was performed have higher risk for APE To Occur Than patients in group 1 to whom pre and post-operative color doppler ultrasonography was routinely applied.

KEYWORDS: Color Doppler Ultrasonography, Total Hip Replacement, Dvt, P

ARTICLE DETAILS

Published On:
02 July 2022

Available on:
<https://ijpbms.com/>

INTRODUCTION

Orthopedic and trauma surgery carries a high risk of deep vein thrombosis (DVT) in the lower limbs and acute pulmonary embolism (APE). Before the advent of antithromboembolic prophylaxis, the frequency of DVT in this type of surgery was about 45–69% versus the 17-40% found in general and gynecological surgery (1, 2). A significant frequency of concurrent DVT has been documented in studies of individuals with confirmed APE (up

to 61%) and the case fatality rate for APE varies from roughly 60% to less than 1%, depending on the clinical presentation (3,4).

In traumatology, the greatest risk is in hip fractures of the proximal extremity of the femur, especially those of the neck, and intertrochanteric fractures (around 59.2%) (5). The study showed that the incidence of DVT is 33.2% preoperatively and 48.7% postoperatively in total hip fractures. It also

The Role of Color Doppler Ultrasonography in the Prevention of Thromboembolic Disease after Total Hip Replacement

showed that distal tibial fractures of 76 patients, which is one of the peri-ankle fractures, has 19.7% incidence risk of DVT preoperatively and 18.6% risk postoperatively. According to another study, the mean time to presentation for symptomatic DVT is 19.5-25.5 days and the mean time to presentation for symptomatic APE is 9 to 22.5 days (6). In orthopedics the risk of thromboembolic complications (TEC) is particularly high in hip and knee surgery, especially in prosthetic replacement, as general factors

are associated with local factors such as trauma to vessels and / or blood stasis which further aggravate the perioperative imbalance of the coagulation system (6,7,8,9). In particular, hip replacement surgery is the one that shows a higher frequency of DVT (especially affecting the proximal large vessels), and of TEC, so much so that pulmonary embolism is one of the main causes of death after this intervention (10, 11).

A study conducted at the Orthopedic Clinic of Florence has shown that the incidence of DVT and TEC after total hip replacement is actually greater than what the clinical picture might suggest as post-operative checks have highlighted numerous asymptomatic cases; The color doppler ultrasonography control performed in 45 days showed a high number of DVT that had occurred after the patient was discharged.

Studying DVT and TEC after total hip replacement has been shown that the surgeon and the anesthetist can directly influence the incidence of these complications. Some authors (12) found that the odds ratio of short surgical hip surgery to cause venous thromboembolism is between 0.86 -0.98 while longer surgical procedures had an odds ratio of 1.10-1.27 which shows that the association between venous thromboembolism incidence and the longest procedures is significant.

Authors (14) demonstrate how epidural anesthesia with the administration of epinephrine and sodium nitroprusside leads to a lower incidence of DVT compared to cases operated in epidural with intravenous infusion only (10-14% versus 25% of DVT).

The importance of the type of anesthesia is also reported by other authors

(15) that show a lower incidence of DVT after total knee replacement with spinal-epidural anesthesia than in patients operated on under general anesthesia.

In a previous study we tested a clinical-anamnestic-instrumental protocol (echocardiogram, venous Doppler, color doppler ultrasonography, perfusion scintigraphy). This protocol has shown considerable diagnostic-preventive reliability, but the number and the invasive characteristics of some tests have not allowed its routine application, so we have developed a new, more streamlined and applicable protocol on all patients.

GENERALITY AND EPIDEMIOLOGY

Deep vein thrombosis (DVT) and acute pulmonary embolism (APE), which are pathological conditions that can be understood under the topic of Pulmonary Thromboembolic Disease, represent a relevant clinical problem as they are complications burdened by high morbidity and mortality. Their incidence, already very high, is constantly increasing due to the lengthening of the average life span, the prolonged survival of patients with neoplasms, chronic infections, cardio or pulmonary diseases, the increase in traumatic pathology of the lower limbs and extension of surgical interventions to more and more large segments of the population. These diseases therefore have a marked social and economic impact secondary to the high mortality of which the APE is burdened.

The incidence of DVT is estimated to be approximately 900,000 cases / year in the United States (15). This disease would be responsible for several hundred thousand hospitalizations / year. Still in the United States the incidence of APE has been calculated at around one-third of venous thromboembolism cases / year and that of DVT has been calculated at around two-third of the cases / year(16).

The indissoluble causal link between DVT and APE implies that the key point to reduce the incidence and mortality from APE depends on correct prophylaxis, timely recognition of cases of DVT, patients' risk factors and methods of detection (16, 17). It is estimated that the use of effective prophylactic measures can save 4000 to 8000 lives every year among patients undergoing surgery.

The risk of DVT is highest in patients over 40 years of age undergoing abdominal or pelvic surgery for malignant neoplasms, under general anesthesia lasting more than 30 minutes (18, 19, 20) and in patients undergoing orthopedic surgery. DVT is established early, sometimes already during the surgery or in any case within the first 72 hours and originates in 2/3 of cases, in the veins of the legs, especially in the venous sinuses of the calf where the flow is particularly slow due to the position and immobility of the patient.

In addition to post-surgical situations, many other pathological conditions, such as myocardopathies and left ventricular failure, neoplasms, burns, infections, diabetes, pregnancy, use of oral contraceptives and myeloproliferative diseases can lead to a high risk of DVT where the risk may be further increased by age.

CLINICAL NOTES

The clinical picture of DVT is characterized by pain, tension and edema, which can sometimes be associated with nocturnal cramps, redness or cyanosis, the appearance of collateral circulation ("Sentinel veins" by Pratt), increased skin temperature, positive Homans sign, formation of a palpable venous cord (secondary to satellite superficial phlebitis due to the propagation of a DVT through the

The Role of Color Doppler Ultrasonography in the Prevention of Thromboembolic Disease after Total Hip Replacement

perforating vein); almost constant signs consist of a change in texture of the skin and muscle masses ("kneading") and an otherwise inexplicable fever.

However, the poor accuracy of the clinical diagnosis of DVT should be emphasized (21, 22) especially in the diagnosis that is neither specific nor sensitive. The low sensitivity is due to the fact that if the thrombosis is not completely occlusive at the level of the proximal venous circulation or is not associated with vascular or perivascular inflammation, it may not determine the appearance of any symptoms.

This is especially true for the bedridden patients in whom the low resistance of the superficial circulation (internal saphenous) offers adequate drainage even in the face of occlusive thrombosis of the superficial-popliteal femoral axis. In fact, in the bedridden patient, the classic clinical picture of DVT appears only in the presence of a significant obstruction of the common femoral vein, into which the deep venous axes of the thigh (deep femoral vein, external circumflex, medial circumflex), the leg (superficial femoral vein) and internal saphenous vein converge.

On the other hand, the symptoms and clinical signs of DVT can be reproduced by many other clinical conditions such as muscle-tendon and osteo-articular diseases, alterations of the lymphatic circulation or alterations of the venous circulation of other nature (superficial phlebitis, post-thrombophlebitic syndromes, deep valvular insufficiency, extrinsic compression, neoplastic infiltration of the iliac vein or inferior vena cava).

More specific are the clinical pictures defined as phlegmasia alba dolens and phlegmasia coerulea dolens. In the first case the limb appears "milky" white, cold and edematous due to an iliac-femoral thrombosis which, however, still has a certain capacity for compensation because it is not totally occlusive, or because it is associated with minor collateral circles. In the second case, marked edema of the limb is associated with cyanosis, in the presence of a totally occlusive iliac-femoral thrombosis which also involves the superficial veins and the communicating veins. The important venous hypertension and the edema thus determined also reduce the arterial flow due to the increase in tissue resistance causing severe ischemic suffering of which the paresis of the limb is the first sign and can lead to venous gangrene.

It must be kept in mind that a "phlegmasia alba dolens" can be symptomatic of partial obstruction of the inferior vena cava by an oligosymptomatic floating thrombosis originating from the iliac axis of the contralateral limb: the stasis thus caused in the opposite iliac axis causes a sudden and severe retrograde thrombosis.

DVT can be defined distal if it affects only the deep veins of the calf where, in most cases it originates, or proximal if it affects the deep venous system in a tract between the popliteal vein and the iliac vein. In the first case, the risk of APE is low and of little clinical significance since it is in any case with small emboli dimensions. Conversely, when DVT extends to

the proximal circulation, the risk of APE increases considerably.

DVT favors the left lower limb due to the compression exerted on the left iliac vein by the right iliac artery and is bilateral with a greater frequency than could be assumed based on clinical data.

HEMATOCHEMICAL INVESTIGATIONS

It is very useful to evaluate the pathophysiological alterations of blood (especially haemostatic phenomena) which can be connected in different measures with the onset of thromboembolic phenomena. In the presence of high levels of fibrinogen, an increase in ESR and an alteration of the hematocrit can be noted.

The fundamental purpose of the haemostatic function is, essentially, to guarantee the circulatory function an adequate volume of blood that has certain physical characteristics such as to allow it to flow through the vessels. Any abnormality that occurs in the coagulation or anticoagulation subsystem can affect the general balance of this delicate physiological process.

The evaluation of those parameters that can be linked to the onset of thrombotic or thromboembolic phenomena is important:

- bleeding time (or haemorrhage) is the time necessary for bleeding from lesion of small vessels to stop (normal value 1-3 min.);
- aggregation from exogenous ADP (photometric method according to Born); the circulating platelets are not all in the isolated state but a portion of them can be found in a state of reversible aggregation. These aggregates can be stabilized at the time of collection (in our case with exogenous ADP) and subsequently compared with unstabilized samples. The resulting aggregate share is expressed as a percentage (normal values 40-60%);
- quick time (of prothrombin) is the time necessary for a plasma poor in platelets to clot to recalcify in the presence of optimal levels of factor III. In practice, it measures the activity of factors II and VII (normal value 80-100%), partial thromboplastin time (PTT) and the time required for fibrin to form a platelet-poor plasma, in which factor III and XII are present. This time measures the reactivation of only the plasma factors of the intrinsic and common pathways (normal value 23-36 seconds);
- antithrombin III

INSTRUMENTAL DIAGNOSTICS

Instrumental diagnostics includes invasive methods (phlebography) and non-invasive methods (radiolabeled fibrinogen uptake test, plethysmography, CT, MRI, ultrasound diagnostics, color doppler ultrasonography).

The Role of Color Doppler Ultrasonography in the Prevention of Thromboembolic Disease after Total Hip Replacement

Phlebography

The "gold standard" for the detection of DVT is still considered to be phlebography (also known as venography) (23) of the lower limbs through a direct radiological demonstration of the thrombus as a constant filling defect, therefore present in at least two projections (24): the fresh thrombus appears as a transparent defect of cylindrical shape inside the lumen of the opacified vein, surrounded by a thin line of contrast medium whose disappearance indicates the adherence of the thrombus itself. The proximal end of a thrombus may appear thinned, elongated and floating freely in the lumen of the vessel: the detachment of this floating portion leaves an upper border of the thrombus clean and linear ("cut off") and usually occurs at the confluence of large collateral veins. The subsequent retraction of the thrombus gives rise to a radiological image of irregular narrowing of the vessel.

Indirect radiological signs of DVT are the lack of opacification of one or more veins of the deep circulation, the presence of collateral circulation, an abrupt stop of injection or the presence of a filling defect in a single projection. In cases of extensive DVT and associated with marked edema and inflammation, a lack of opacification of the entire deep venous system can be observed. Phlebographic signs of previous DVT are the presence of collateral circulation and an irregular narrowing of the recanalized veins which also appear devoid of valves.

For its execution, classical ascending phlebography requires the apposition of laces which excludes the superficial circulation from the transit of the contrast medium that is injected into a dorsal vein of the foot or into the terminal saphenous vein in countercurrent (25).

Despite a good diagnostic accuracy, estimated at around 91% if performed by expert hands and with a high quality standard, venography is an invasive method but is tolerated by the patient and not entirely free from complications. These complications are represented by possible reactions to the injection of the contrast medium, from skin necrosis due to extravasation of the contrast medium, to the possibility (however very remote) of pulmonary embolism due to thrombus mobilization and post-phlebographic thrombosis (26).

The latter would be due to the combined effect of the pre-existing alteration of the venous wall and the damage caused by the contrast medium on the endothelial cells due to the direct chemotoxic effect and its high osmolarity. In fact, the incidence of post-phlebographic thrombosis, like the rest of the other complications, can be reduced with the use of non-ionic contrast media (26).

It must be borne in mind that even with venography, both false negatives and false positives are possible. The former may be due to small thrombi of dimensions inferior to the spatial resolution of the contrast, to isolated thrombosis of the

deep femoral vein or to duplication of the popliteal or femoral vein. False positives are caused by flow artifacts misinterpreted as fill defects. Finally, it must be remembered that in a certain percentage of cases, venography cannot be performed due to the impossibility of cannulating a dorsal vein of the foot due to marked edema or local infection, or because the patient cannot be transported to a radiology service or if the patient has clear contraindications to the use of contrast media (allergy, nephropathy, multiple myeloma, diabetes, severe hyperuricemia, etc.).

For all the above considerations, venography tends to be increasingly replaced by other non-invasive investigation methods which, as we shall see, equally provide an excellent evaluation of DVT. However, phlebography, which is still considered by most authors to be the only method capable of accurately identifying the isolated thrombosis of the calf muscle veins, is currently unsurpassed for its ability to provide overall anatomical images (non-segmental) and maintain a fundamental role in the following conditions:

- patients with positive non-invasive tests in which there is a relative contraindication to anticoagulant therapy.
- Patients in whom non-invasive tests cannot be performed correctly.
- Patients with symptoms of DVT recurrence if the results of a non-invasive test that failed after the first episode of DVT are not available or if the non-invasive tests are not convincing.
- In all cases in which there is a discrepancy between clinical data and non-invasive instrumental findings.

Radiolabelled Fibrinogen Collection Test

The radiolabeled fibrinogen uptake test (RFUT) is based on the incorporation of ¹²⁵I-labeled fibrinogen in a newly formed thrombus and the consequent possibility of measuring radioactivity with a surface detector. This test is not very specific as all the conditions that involve the local deposition of fibrin (hematomas, wounds, fractures, cellulite, arthritis, edema, ulcerations, extensive varicosities, and superficial thrombophlebitis) determine its positivity. Moreover it has a high sensitivity for distal thrombosis, but a low sensitivity for proximal ones. It also requires repeated sequential examinations for a few days and cannot be performed in pregnant women. Therefore, such a test today finds only two elective indications (27, 28,29):

- asymptomatic patients undergoing general surgery in which pharmacological prophylaxis has not been performed due to high haemorrhagic risk, and in whom the development of a distal DVT is to be recognized early.
- patients suspected of recurrence of DVT in whom a resumption of anticoagulant therapy is expected; in these patients venography is also often not able to discriminate between recent thrombosis and outcomes of previous episodes.

The Role of Color Doppler Ultrasonography in the Prevention of Thromboembolic Disease after Total Hip Replacement

However, this test is currently almost abandoned due to the risk of hepatitis B transmission.

Impedance Plethysmography

Plethysmography is a non-invasive method which is based on the recording of the volume changes of a limb. Particularly, impedance plethysmography is based on the principle that the changes in blood volume produced by a temporary venous obstruction in a lower limb, in which a flow of high-frequency direct current is passed, can be measured as changes in electrical impedance.

Diagnosis of DVT is based on the recognition of changes in venous capacitance and venous emptying rate after temporary flow occlusion. In the presence of occlusive DVT, the venous system is already almost full and therefore at the moment of the cuff insufflation which causes transient stasis, the volume variations of the limb, in particular of the calf, will be minimal. Similarly, when stasis is released, venous outflow is slowed by obstruction and increased resistance through the collateral circulation.

The comparison of this method with venography has shown a high diagnostic accuracy in cases of proximal DVT. False negatives are due to the presence of non-occlusive (often floating) thrombi or a large collateral circulation, while false positives may be due to COPD, congestive heart failure, ascites, pregnancy, compression, ab-extrinsic chronic DVT, obesity, peripheral arteriopathy, poor cooperation, low temperatures (30,31).

Furthermore, this method shows poor diagnostic accuracy in distal forms of DVT. However, there is no full agreement in the literature on the probability of these thrombi to give rise to an APE, and serial repetition of the examination in symptomatic patients allows to identify those in which a distal thrombosis extends proximally and those in which a proximal thrombosis becomes progressively more occluding, allowing a timely recourse to therapy.

Finally, we must not forget how plethysmography is not able to specify the central extension of DVT because the method has a high cost and considerable technical and organizational problems. Despite these limitations, this method is included in many diagnostic algorithms for APE.

Ultrasound diagnostics

The ultrasonic diagnostics of DVT were born with the use of continuous wave Doppler (CW), with very variable specificity and sensitivity resulting in the numerous studies performed. The main limitations of the CW Doppler method, based on the study of single vessels, consisted of the sensitivity at the level of the leg and the considerable subjectivity of the examination which is dependent on the experience of the single observer. However, limited to the diagnosis of proximal DVT, the CW Doppler had a sensitivity of 83% and a specificity of 91% with an overall diagnostic accuracy of 88%. False positives may be due to venous compression from hematomas, edema, and cysts in the

posterior region of the knee, massive ascites, pregnancy, abdominal or pelvic masses, and severe congestive heart failure. False negatives can be secondary to anatomical changes in the venous system (see double superficial femoral) or to the presence of non-occlusive femoral thrombosis with a floating component. The diagnostic accuracy of the method is low in diagnosis of infrapopliteal DVTs; moreover, it is often difficult to document new acute phlebotrombotic episodes in limbs previously affected by similar episodes. Despite these limitations, this method is good for its low cost, transportability and the ease of execution.

Ultrasonic diagnostics have been considerably refined with the use of echotomography which allows direct visualization of the vessels and their contents, while the pulsed Doppler allows to study the flow inside the vessel (Duplex Scanner or Eco-Duplex or Doppler Echotomography).

High resolution ultrasound has virtually changed the diagnostic approach to DVT. The examination is simple, repeatable, non-invasive and can also be performed at the patient's bed.

The ultrasound diagnosis of DVT is based on the following criteria:

- 1) Direct visualization of the thrombotic material with different degrees of echogenicity.
- 2) Absent or poor compressibility of the vein whose volume appears to be increased and with scarce respiratory excursions.

Direct visualization of an intraluminal thrombosis is the most accurate sign for the diagnosis of DVT; the presence of soft echoes inside a venous vessel that appears distended and often totally occluded is diagnostic of an acute thrombosis. For the evaluation of the risk of APE and the consequent therapeutic choices, it is important to study the terminal portion of the thrombus which can sometimes appear floating, loosely adherent to the wall, with a lamellar appearance, while in other cases it is coralliform, less echogenic than the rest parts and more inhomogeneous. These aspects, especially if present at the level of the iliac veins or the inferior vena cava, identify a high embolic risk and direct towards the application of a caval filter and the use of thrombolytic therapy.

The differentiation between chronic forms of DVT is important as they are characterized by the presence of collateral vessels, occluded but not dilated venous segments, or recanalized segments with irregular walls and hyperechoic endoluminal thrombotic material.

The absence of endoluminal echogenic material does not however exclude the presence of a thrombus which, initially, tends to be anechoic or weakly echogenic. In this phase, the diagnosis of DVT also makes use of indirect signs such as poor or non-compressibility of the vessel, valvular fixity, increase in vascular caliber, slow distensibility of the venous wall that follows the release after prolonged compression, and

The Role of Color Doppler Ultrasonography in the Prevention of Thromboembolic Disease after Total Hip Replacement

the poor response to the Valsalva maneuver (however applicable only to the common femoral vein). The non-compressibility of the vein, alone, seems to have, according to some authors, a sensitivity and specificity of 96% and 97% respectively. On the other hand, more recently some authors have reported a scarce usefulness of ultrasound with compression for the screening of DVT in asymptomatic patients in the post-operative phase.

With doppler ultrasound (Duplex Scanner or Echo-Duplex), the study of the flow using pulsed wave Doppler (PW) is associated with the ultrasound visualization of the venous structures. The normal venous flow of the lower limbs (S-sound) is phasic with the acts of breathing (it is reduced in inspiration and increased in expiration). Moreover, the flow stops in response to the Valsalva maneuver or following the manual compression maneuvers proximal to the Doppler signal recording site and accelerates promptly following distal compressions (A sound). Additional diagnostic criteria for DVT, partly derived from Doppler velocimetry and which add to direct visualization of thrombotic material, are:

- 1) Absence of spontaneous and provoked flow in the occlusive DVT host vein.
- 2) Loss of flow phasing with breathing or with the Valsalva maneuver, upstream of the occlusion.
- 3) Slowing of the flow transmission downstream of the occlusion.
- 4) Acceleration of the marginal flow and poor modulation induced in the case of non-occlusive DVT.

The visual safety of flowmetric sampling using PW Doppler (compared to the spatial indeterminacy of the CW Doppler) has also allowed the directional study of the collateral circulation, allowing to appreciate with certainty the existence of flow inversion in a vein or in its segments, testimony of the attempted initial compensation of the obstruction (indirect signs).

Comparative studies between phlebography and Echo-Duplex have shown, for the latter method, a sensitivity of 93%, a specificity of 98%, a positive predictive value of 98% and a negative predictive value of 94% (39,27). Sensitivity, however, is reduced when an infrapopliteal thrombosis is sought (78%); another site of difficult exploration may be the adductor hiatus. However the Echo-Duplex is a safe, accurate technique and can also be performed during pregnancy, which allows the differential diagnosis of lesions that can simulate the clinical picture of a DVT (hematoma, Baker's cyst).

On the other hand, the use of the color doppler ultrasonography has achieved a real one "diagnostic revolution" in the field of DVT, thanks to the simultaneous visualization of the echo-tomographic image, the color-coded vascular flow (33) and the spectral analysis of the flow obtained with Doppler PW (Eco-Triplex). This association allows to obtain a real "Functional Ultrasonic Phlebography".

It allowed to safely differentiate the floating thrombus (surrounded by a thin color ring in cross section) from the partially adhered thrombus and from the occlusive thrombus. This helps to specify the proximal and distal extension of the DVT and increase the safety of retrieval of thrombi at the level of the deep veins of the soleus and calf, of the iliac vein.

According to some authors (34,35) Color Doppler Ultrasonography has radically changed the reliability of the ultrasonic examination in finding a thrombosis in the iliac districts and in the calf, even if in the latter district optimal results are not achieved in comparison with phlebography (sensitivity 76%, specificity 86%). However, some authors (36) have shown that an iliac or calf thrombosis can be identified, by means of color doppler ultrasonography, in about one third of patients who have a femoro-popliteal DVT. In addition, 15% of patients with DVT on color doppler ultrasonography have isolated iliac or calf thrombosis. Therefore, in consideration of the high percentage of patients in which a good visualization of at least one iliac segment (79%) and of the three veins is obtained of calf major (76%) and in consideration of the short time required, the authors concluded the inclusion of Color Doppler Ultrasonography for suspicion of DVT in all patients at the iliac and calf level.

On the other hand, it is legitimate to ask whether the recognition of a distal DVT is really important. Not all authors agree on the possibility that distal DVT results in APE. Other authors highlight the possible extension of a distal DVT in the popliteal-femoral direction with consequent risk of APE. Hence, it's important to repeat the exam after 7-10 days in doubtful cases and when methods that are not very sensitive below the knee.

Furthermore, Color Doppler allows the identification of the deep femoral vein and circumflex veins (real "ghosts" to phlebography) and is superior to ultrasound alone in the differentiation between acute DVT and chronic venous alterations. Finally, it allows easy recognition of particularly frequent anatomical variants, such as the duplication of the popliteal vein or the superficial femoral vein. Potential limitations of Color Doppler are its inability to identify small non-occluding thrombus, and visualization difficulties determined, especially in the calf, by the presence of edema. Finally, we must not forget how reverberation artifacts can mimic the presence of a thrombus, especially at the popliteal level.

Nuclear Magnetic Resonance (RMN)

Among the other diagnostic methods for DVT, MRI deserves to be mentioned which, despite the well-known limits of availability and high cost and non-transportability, it can be indicated in particular clinical situations with suspicion of iliac vein thrombosis and inferior cava or in cases where a distinction must be made between acute and chronic thrombosis or as a complete examination where the results of

The Role of Color Doppler Ultrasonography in the Prevention of Thromboembolic Disease after Total Hip Replacement

other tests are doubtful and inconclusive. The MRI signal of a normal vessel is that of an empty vessel because the blood that receives the magnetic stimulation is no longer the one that reflects the signal. Thrombosis provides a finding instead of a "full" vessel. A further fine-tuning is magnetic resonance angiography.

The investigation is often unwelcome to the patient and has considerable limitations (pacemakers, metal prostheses, etc.). In a group of 36 patients in which MRI and venography were performed, the sensibility and specificity of MRI for the diagnosis of DVT were 90% and 100%, respectively.

Computed Tomography

Computed tomography (CT) occupies a place similar to that of MRI, but, unlike the latter, it is easier to find and access. For the diagnosis of DVT the use of contrast medium (Angio-CT) is often necessary.

At the end of this review of diagnostic methods for DVT, we cannot forget the role that the laboratory can play. It is in fact possible to document a state of coagulation activation through the detection of increased levels of the activation fragment of prothrombin F1 + 2, of fibrinopeptide A and of the Thrombin-complexes, indices of increased thrombin formation, and an increased degradation of stabilized fibrin by the measurement of D-Dimers.

Numerous controlled clinical trials have evaluated the clinical utility of such laboratory investigations in excluding or confirming the clinical suspicion of DVT. The determination of the concentration of fibrin degradation products was the only test with a high negative predictive capacity. In fact, the identification of the D-dimer Elisa (expensive and time-consuming method) and of the D-dimer Latex B (faster and cheaper) has a sensitivity for DVT equal to 94%, a sensitivity approaching 100% in proximal forms, but with low specificity. Therefore, some authors (37) have proposed these methods as the first screening test (naturally only with negative predictive value) in the search for DVT. This algorithm would make it possible to reserve imaging methods (ultrasound or phlebography) only for patients with positive D-dimer search and to those with negative search but high clinical suspicion.

PROPHYLAXIS

The advent of prophylaxis has led to a sharp decline in DVT in orthopedic-trauma surgery and a reduction in the prevalence of APE (38); The risk of iatrogenic haemorrhagic complications, with the functional and infectious consequences that can be accompanied, means that often the prophylaxis performed has not been effective for prevention. DVT prophylaxis can be performed with physical and pharmacological methods (39).

Physical methods

- Calf pump, isometric calf contractions, active hip and knee mobilization, early resumption of walking by fighting stasis,

reduce the risk of DVT (40).- Elastic restraint of the lower limb with elastic stockings (less demanding), or bandages (more demanding but adaptable from case to case).

Such methods are often associated with drug treatments as they alone reduce the risk of DVT by only 25% (40).

- Intermittent external pneumatic compression implemented with compressible air chambers on the calf and thigh. During the compression phase the venous flow doubles. It is a method that decreases the risk of thromboembolic disease by 60% but leaves a proximal DVT rate of 10-15% in total hip replacements; however, this method is expensive, cumbersome, demanding for doctor and patient, not tolerated by 10% of orthopedic patients (41,42) and which cannot be continued at discharge.

- "AV impulse"; it is a disposable shoe and a compact electric pump that create a 20" cyclical compression to the plantar venous arch. It increases the venous return and manages to overcome the obstacle of a pneumatic lace placed on the calf and inflated up to at 100 cm Hg. Some authors (43) report a lower incidence of DVT with pulse AV compared to a group treated with heparin.

Pharmacological methods

- Anti-vitamin (K).

There are numerous studies, especially of North American origin, which demonstrate the preventive efficacy of Warfarin (the most used molecule of these drugs) especially on the reduction of proximal DVT (44, 45, 46). However, these molecules, which offer effective and economically advantageous prophylaxis, have numerous limitations: delay of action, individual reactivity that requires constant medical surveillance to continuously adjust the dose making it difficult to use at home, the existence of numerous contraindications to their use and last but certainly not least, a high bleeding risk (even if some protocols report much lower bleeding risks compared to classic protocols). That's why its use in European countries is very limited.

- Unfractionated heparins.

These 12000 and 15000 molecular weight heparins are used with 2 protocols, at adjusted dose (for weight and blood tests) according to the Leyvraz scheme (47) and at low and fixed dose (48).

Fixed-dose heparins reduce the risk of DVT by 50% but a DVT rate remains of 12-15% after total hip replacement and 30% in trauma (49, 50). This method has the advantage of being simple to perform for the doctor and patient, with few contraindications and with little risk of bleeding.

Dose-adjusted heparin has a slightly better efficacy, residual DVT 10-15% in orthopedics and 20% in trauma (49) but presents a higher risk of bleeding and more difficult to manage, so it is little used.

- Low molecular weight heparins

These are heparins with an average molecular weight of 5000. These heparins are establishing themselves as the most

The Role of Color Doppler Ultrasonography in the Prevention of Thromboembolic Disease after Total Hip Replacement

widely used pharmacological means for the prophylaxis of DVT in orthopedics and traumatology (50); residual DVTs are 10-12% (5% proximal DVT) (51, 52). Their risk of bleeding is equal to that of fractionated heparins (around 1.8%), their administration is easy, the protocols relatively simple and the contraindications are minimal.

- Dextran

This polysaccharide molecule presents risks of both circulatory and allergic overload. In traumatology (femoral neck fractures) the residual DVT rate is 30% (53). Although it reduces thromboembolic risk by 40%, it has been shown to be less effective than other physical and / or pharmacological methods.

- Antiplatelet agents

The most used is Acetylsalicylic Acid.

Studies shows a reduction of DVT in trauma by only 15% (54, 55); nevertheless it shows a marked prophylactic effect on APE with a reduction of 60% -70% (in orthopedics from 5.9% to 2.5%, in trauma from 7.6% to 2.9%).

Imperiale (56) comparing 91 treatment groups and 25 control groups reported by the literature of the last years, affirms that all prophylactic methods lower the risk of DVT except aspirin.

- Direct oral anticoagulants In the early 2000s, the use of direct oral anticoagulants such as Xarelto (Rivaroxaban) has increased. Rivaroxaban, an oral factor Xa inhibitor, may offer a straightforward, fixed-dose regimen for treating acute DVT and maintaining treatment without the requirement for laboratory monitoring. It provides a straightforward, single-drug strategy to the short-term and long-term therapy of venous thrombosis, which may improve anticoagulation's benefit-to-risk ratio (61).

Rivaroxaban, like the other factor Xa inhibitors, is as effective as or better than warfarin (Coumadin) in avoiding recurrent DVT, nonfatal PE, and fatal PE in the short term (three months), with no differences in mortality or bleeding events (62).

Advantages of Rivaroxaban is that it is easily manageable (similar to heparins) when administered orally and regular monitoring of coagulation parameters is not required. However, it is costly and there is limited clinical experience with these drugs. Also, it is not recommended, and partially contraindicated, in patients with artificial cardiac valves and it is not suited for patients with valvular atrial fibrillation.

Warfarin on the other hand has well-known effects and side effects and it has low costs. However, it has its disadvantages. It is difficult to manage because it has a long half life, and it requires regular monitoring of the PT/INR (as vitamin K antagonists affect the extrinsic coagulation pathway). Warfarin also has a broad range of drug interactions, and it is not suited for acute therapy of PE or DVT.

- Secondary PE prophylaxis with color doppler ultrasonography

SECONDARY PROPHYLAXIS OF PE

In addition to primary prophylaxis, there is a secondary PE prophylaxis, represented by the highlighting and treatment of the process in an asymptomatic phase before it gives a clinically evident commitment. There are numerous contributions that show that proximal and distal DVT can be highlighted in the asymptomatic phase (57) with routine control of all patients with venous venography or color doppler ultrasonography. The latter has the advantage of being non-invasive, portable, without side effects, less expensive, repeatable several times for control during the treatment of DVT. Its reliability is discussed in literature, some authors (58) report low sensitivity, accuracy and specificity values, while others (59) report a high reliability of this instrumental investigation. These conflicting data are probably linked to the fact that this method is "dependent performer".

In one of our studies (60) on hip prosthesis patients we found, with routine Doppler ultrasound, an incidence of asymptomatic DVT of 7.3%; the treatment of the proximal ones with IV continuous infusion heparin and the control of the distal ones meant that no embolization occurred in this group, while in the control group (clinical surveillance only) a thromboembolic event occurred in 4.6% of cases.

Despite physical and pharmacological prophylaxis, in orthopedic surgery the residual rate of DVT is around 10-15%; for this reason, given the possibility of early diagnosis of DVT when they are still in the asymptomatic phase, we believe it is essential to use the color doppler ultrasonography as a means of screening to be applied in all interventions at risk to carry out a valid secondary prophylaxis of thromboembolic disease.

MATERIAL AND METHOD

The material of this paper consists of 420 patients operated on for total hip replacement at the 1st Orthopedic Clinic of the University of Florence and other private clinics in the period between 1994-1996. These are 286 first cemented implants, 36 first hybrid implants, 38 first cementless implants and 60 hip replacement reviews.

There are 266 women and 154 men. In all patients antithromboembolic prophylaxis was performed with Calciparin sc 5000 IU 3 times / day from the day of surgery to the date of discharge and 5000 IU 2 times / day for another 2 weeks. Patients have calf pump exercises from the day of surgery, active hip and knee mobilization, and isometric quadriceps contractions from the next day; elastic compression has been used in patients at risk. The sitting position was achieved after three days, loading and walking after six to seven days. All patients were operated on under epidural or subarachnoid anesthesia.

The method was based on an instrumental clinical-anamnestic protocol developed with the Angiology service of the CTO. This protocol, as well as on the clinical-anamnestic evaluation and routine blood chemistry tests, is essentially

The Role of Color Doppler Ultrasonography in the Prevention of Thromboembolic Disease after Total Hip Replacement

based on the venous color doppler ultrasonography examination of the lower limbs which is performed preoperatively and postoperatively on the fifth-sixth day before moving on to loading and walking, lung scan. perfusion was performed only in case of clinical doubt of embolization.

The 420 patients operated on for total hip replacement were divided into 2 groups:

- 248 patients (group 1) to whom the protocol was routinely applied (color doppler ultrasonography and lung perfusion scintigraphy);
- 172 patients (group 2) in which only clinical control was performed and instrumental tests were performed only in case of clinical doubt.

RESULTS

In group I, (routine preoperative color doppler ultrasonography), the preoperative venous color doppler ultrasonography examination revealed 8 cases (3.2%) of deep vein thrombosis (4 proximal and 4 distal). Of these patients, 6 underwent thrombolytic therapy until the resolution of the picture (always controlled with color doppler ultrasonography) and subsequently operated on hip prostheses without problems and was operated on immediately (femoral neck fracture) after having applied a caval filter.

Also in group 1, the postoperative color doppler ultrasonography examination performed on the 7th day and in any case before the resumption of walking revealed 22 cases (8.9%) of deep vein thrombosis: in 16 cases it was venous thrombosis affecting the proximal large vessels (12 ipsilateral, 2 contralateral and 2 bilateral) and in 6 cases of

venous thrombosis affecting the venous vessels of the leg. In 18 patients with DVT, there were no clinical symptoms, in 4 there was a positive clinic. All proximal deep vein thrombosis was treated with continuous IV infusion of heparin until the embolic risk was resolved (disappearance of the floating thrombus, always evaluated with color doppler ultrasonography controls performed every 3-4 days) and subsequently with Warfarin for 4-6 months.

The evolution of distal DVT was followed by repeated color doppler ultrasonography examinations to detect any propagation to proximal vessels, an event that never occurred. APE did not occur in any patient in group I.

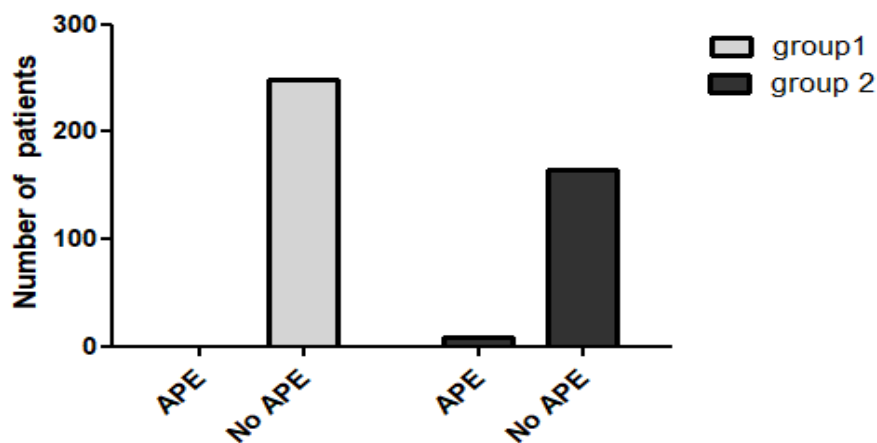
In patients of group II (clinical control and only possibly instrumental) the clinical doubt of DVT, confirmed later with color doppler ultrasonography, occurred in 8 cases (4.7%): 8 proximal DVTs.

There were 8 cases of APE in this group:

- 2 case in a patient in whom a diagnosis of proximal DVT had already been made (one of the eight cases mentioned above);
 - 4 cases 12 days after surgery, with already resumed walking, with sudden pulmonary symptoms without the presence of clinical signs of DVT. In these cases, however, the venous color doppler ultrasonography has revealed proximal venous thrombosis with floating thrombus;
 - 2 cases 3 weeks after surgery when the patient was at home. Also in these cases, contrary to the clinical picture, the venous color doppler ultrasonography revealed a DVT of the proximal great vessels.
- All patients with APE were transferred to intensive care or resuscitation wards; the clinical pictures have fortunately always resolved.

Statistical Analysis

Data analyzed	APE	No APE	Total
group1	0	248	248
group 2	8	164	172
Total	8	412	420



Group 1: Clinical control ultrasonography and lung perfusion scintigraphy

Group 2: Clinical control

The Role of Color Doppler Ultrasonography in the Prevention of Thromboembolic Disease after Total Hip Replacement

Results: Significant relationship was found between APE and protocole used to follow the patients (Pvalue 0.0007). Patients (group 2) in which only clinical control was performed have higher risk to occur APE than patients (group 1) to whom the previously described protocol was routinely applied (Odds ratio 25.68; CI "1.471 to 448.3").

The analysis of data was carried out using GraphPad Prism version 5 for Windows (GraphPad Software, La Jolla California USA, www.graphpad.com). The Fisher's exact test was used to determine if there is a significant relationship between categorical variables. Odds ratio was calculated by adding 0,5 of each value.to report the strength of association between variables. A probability value of less than 0.05 was regarded as statistically significant.

CONCLUSIONS

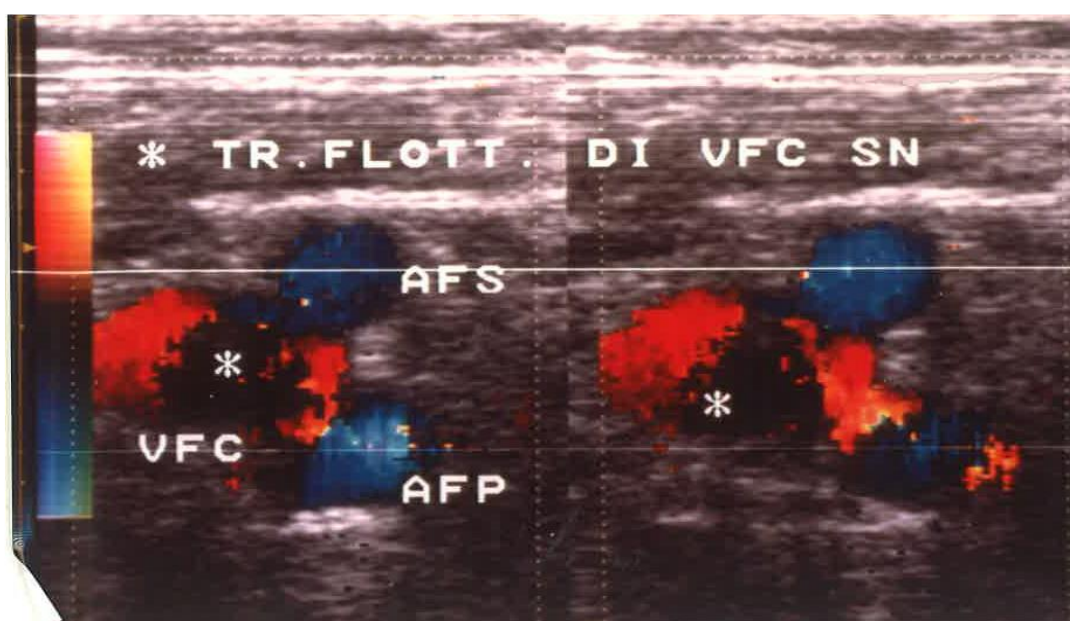
Trauma orthopedic surgery carries a high risk of thromboembolic complications which has been considerably reduced by the introduction of prophylaxis which currently makes use of pharmacological and physical methods.

Despite this, in this type of surgery, and in particular in hip replacement, the residual rate of DVT is around 10-15% and therefore secondary prophylaxis, i.e. the early diagnosis of DVT, when they are still in the asymptomatic phase, before they manifest themselves with pictures of APE.

Among the tests used for this secondary prevention, color doppler ultrasonography has significant advantages over venography:

- non-invasive.
- portable;
- without side effects;
- less expensive;

INDEX



Floating thrombus of the left common femoral vein

- Repeatable several times.

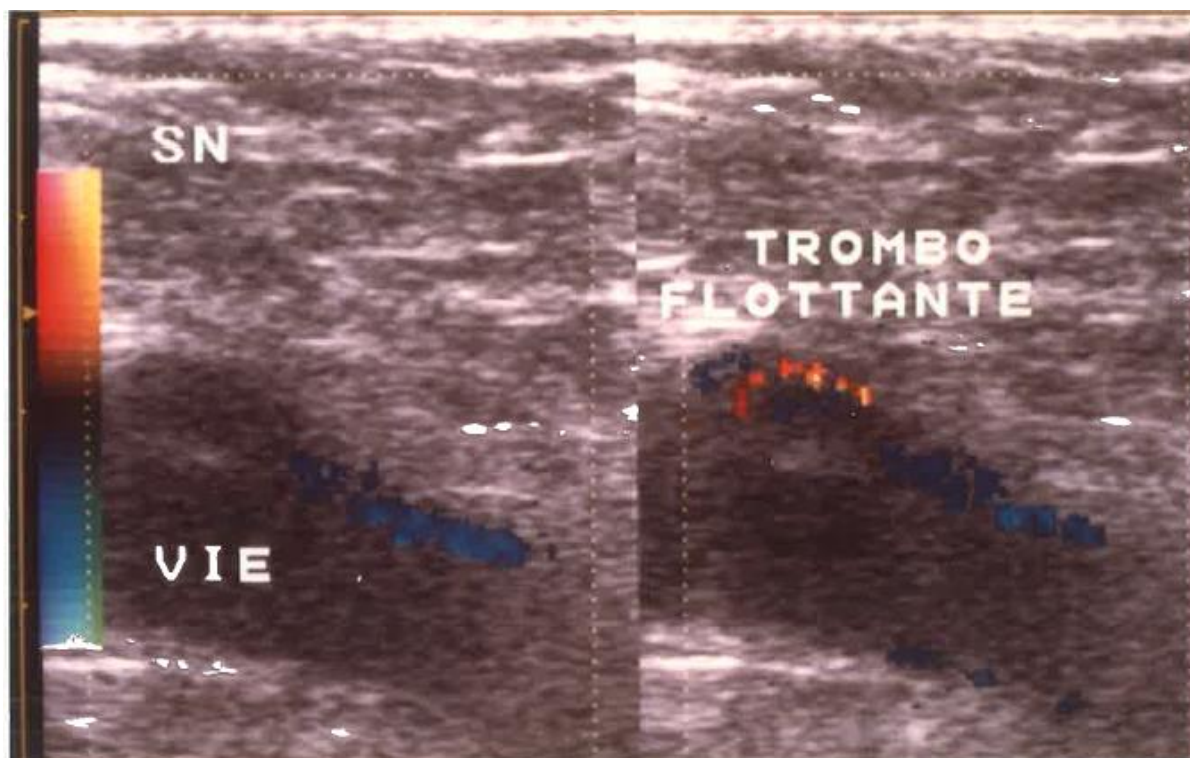
In the literature, conflicting data on the color doppler ultrasonography are found: some authors (58) report low values of sensitivity, accuracy and specificity, others (59) instead note a high reliability of this survey.

From the examination of our results we can affirm that the pre- and postoperative color doppler ultrasonography examination in patients operated on for total hip replacements plays a fundamental role in the prevention of DVT, highlighting asymptomatic preoperative cases, and especially in the secondary prevention of PE as it allowed us to highlight and treat asymptomatic cases of DVT even with floating thrombi of the proximal large vessels, before they probably manifested themselves with embolization, which was never seen in patients of group I.

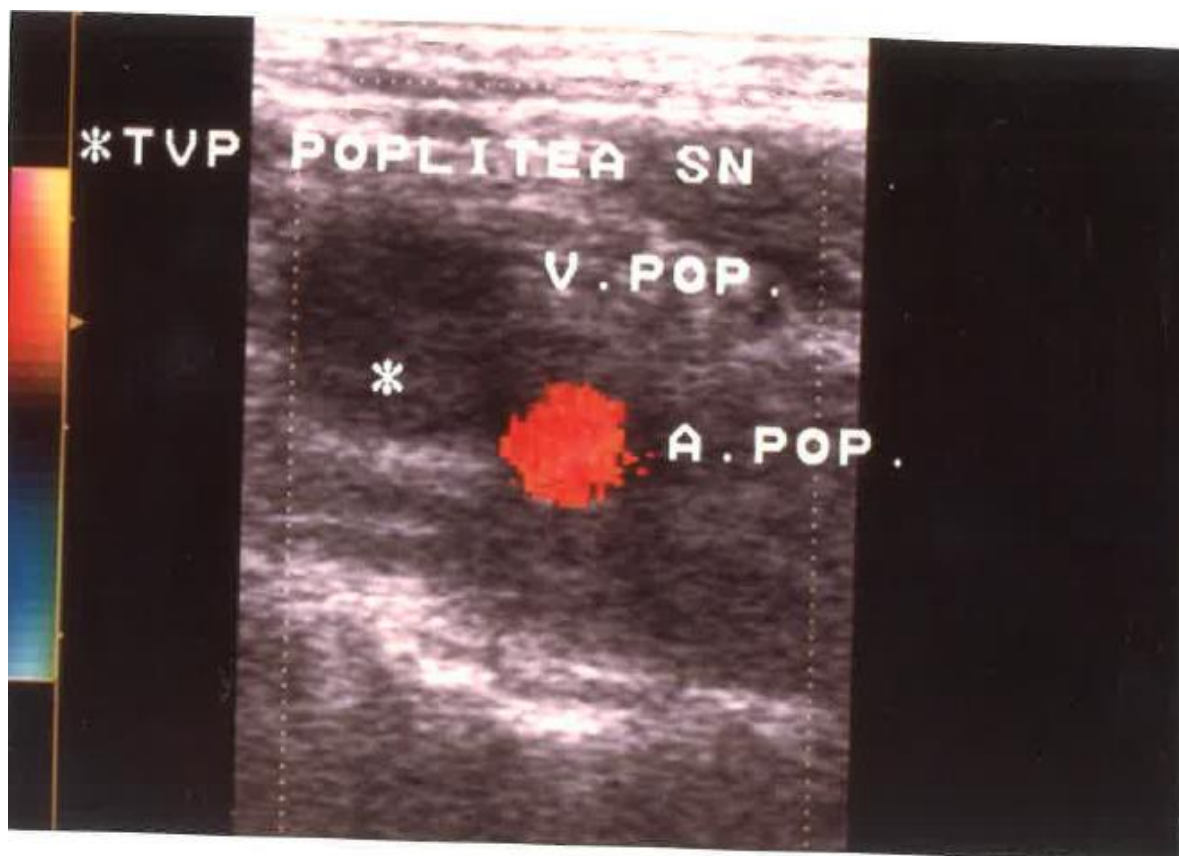
This data is confirmed by the fact that in group II (instrumental control only in case of clinical doubt) there were 8 cases of PE, which manifested itself, in 6 out of 8 cases in primis, with pulmonary involvement. These 6 patients also showed, contrary to the local clinical picture, positivity to the venous color doppler ultrasonography control which highlighted in all of them a DVT of the proximal large vessels.

Our results were confirmed by the statistical analysis that showed that a significant relationship was found between APE and the protocole used to follow the patients, with a Pvalue of 0.0007. Patients (group 2) in which only clinical control was performed have a higher risk for APE to occur than in patients (group 1) to whom the previously described protocol, which incorporated color doppler ultrasonography, was routinely applied.

The Role of Color Doppler Ultrasonography in the Prevention of Thromboembolic Disease after Total Hip Replacement

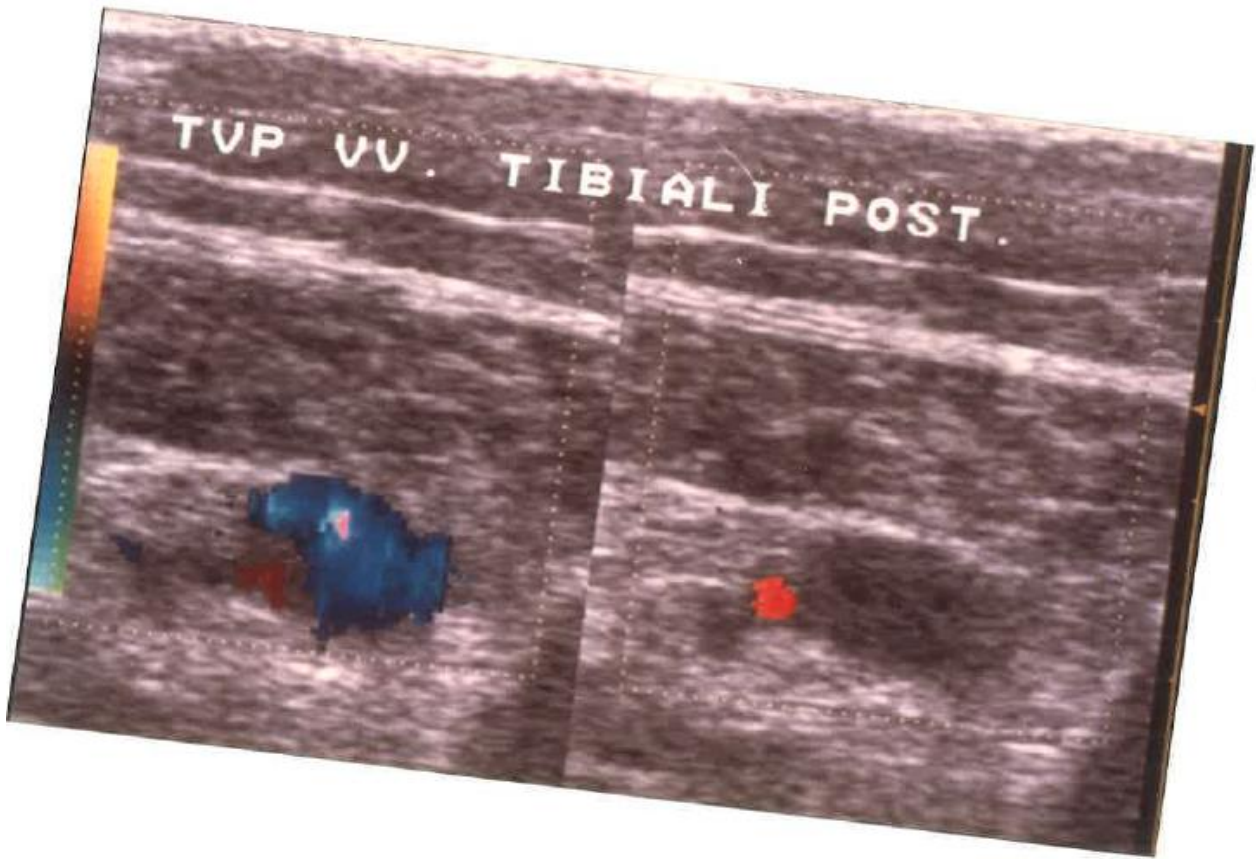


Floating thrombus of the left external iliac vein

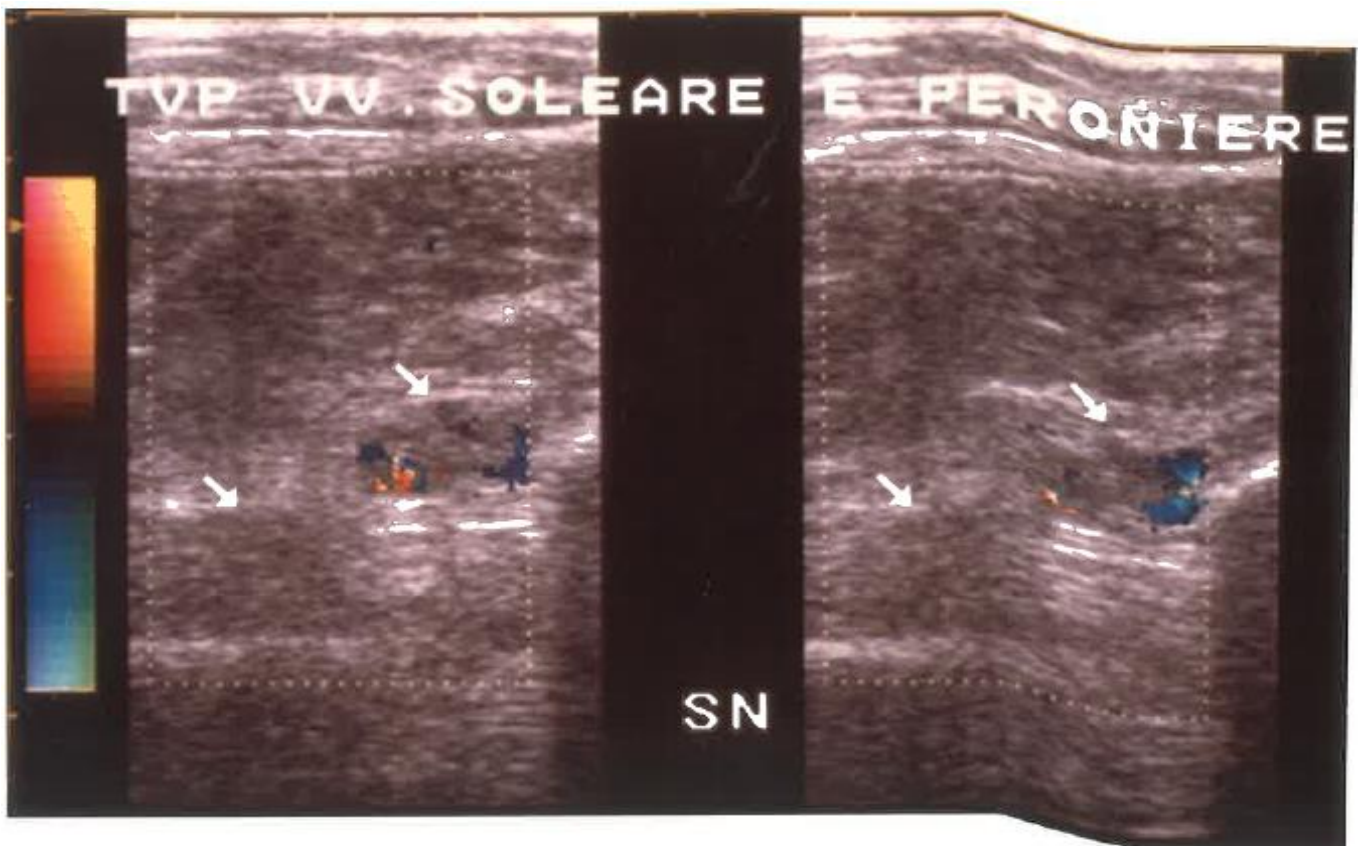


Deep vein thrombosis of the left popliteal vein

The Role of Color Doppler Ultrasonography in the Prevention of Thromboembolic Disease after Total Hip Replacement



Deep vein thrombosis posterior tibial veins



Deep vein thrombosis of the solar and peroneal

The Role of Color Doppler Ultrasonography in the Prevention of Thromboembolic Disease after Total Hip Replacement

BIBLIOGRAPHY

- I. Lin, Patrick P., et al. "Deep venous thrombosis after orthopedic surgery in adult cancer patients." *Journal of surgical oncology* 68.1 (1998): 41-47.
- II. Nick, Alpa M., et al. "Risk of Thromboembolic Disease in Patients Undergoing Laparoscopic Gynecologic Surgery." *Obstetrics and Gynecology* (New York. 1953), vol. 116, no. 4, 2010, pp. 956-961.
- III. Jimenez, David, et al. "Prognostic significance of deep vein thrombosis in patients presenting with acute symptomatic pulmonary embolism." *American journal of respiratory and critical care medicine* 181.9 (2010): 983-991.
- IV. Agnelli, Giancarlo, and Cecilia Becattini. "Acute pulmonary embolism." *New England Journal of Medicine* 363.3 (2010): 266-274.
- V. Wang, Hu, et al. "Perioperative incidence and locations of deep vein thrombosis following specific isolated lower extremity fractures." *Injury* 49.7 (2018): 1353-1357.
- VI. Mula, Viswanath, et al. "Venous thromboembolism rates after hip and knee arthroplasty and hip fractures." *BMC musculoskeletal disorders* 21.1 (2020): 1-7.
- VII. Husted, Henrik, et al. "Low risk of thromboembolic complications after fast-track hip and knee arthroplasty." *Acta orthopaedica* 81.5 (2010): 599-605.
- VIII. Zhou, Xindie, et al. "Who are at risk for thromboembolism after arthroplasty? A systematic review and meta-analysis." *Thrombosis research* 132.5 (2013): 531-536.
- IX. Kashuk, Jeffrey L., et al. "Progressive postinjury thrombocytosis is associated with thromboembolic complications." *Surgery* 148.4 (2010): 667-675.
- X. Memtsoudis, Stavros G., et al. "Risk factors for pulmonary embolism after hip and knee arthroplasty: a population-based study." *International orthopaedics* 33.6 (2009): 1739-1745.
- XI. Ryan, Michael G., et al. "Effect of mechanical compression on the prevalence of proximal deep venous thrombosis as assessed by magnetic resonance venography." *JBJS* 84.11 (2002): 1998-2004.
- XII. Kim, John YS, et al. "Surgical duration and risk of venous thromboembolism." *JAMA surgery* 150.2 (2015): 110-117.
- XIII. Sharrock, Nigel E., et al. "Factors Influencing Deep Vein Thrombosis Following Total Hip Arthroplasty Under Epidural Anesthesia." *Anesthesia and Analgesia*, vol. 76, no. 4, 1993, pp. 765-771.
- XIV. Basques, Bryce A., et al. "General compared with spinal anesthesia for total hip arthroplasty." *The Journal of bone and joint surgery. American volume* 97.6 (2015): 455.
- XV. Raskob, Gary E., et al. "Surveillance for Deep Vein Thrombosis and Pulmonary Embolism: Recommendations from a National Workshop." *American Journal of Preventive Medicine*, vol. 38, no. 4, 2010, pp. S502-S509.
- XVI. Toker, Serdar, David J. Hak, and Steven J. Morgan. "Deep vein thrombosis prophylaxis in trauma patients." *Thrombosis* 2011 (2011).
- XVII. Caprini, Joseph A. "Risk assessment as a guide for the prevention of the many faces of venous thromboembolism." *The American Journal of Surgery* 199.1 (2010): S3-S10.
- XVIII. Phan, Kevin, et al. "Anesthesia duration as an independent risk factor for early postoperative complications in adults undergoing elective ACDF." *Global spine journal* 7.8 (2017): 727-734.
- XIX. Felder, Seth, et al. "Prolonged thromboprophylaxis with low molecular weight heparin for abdominal or pelvic surgery." *Cochrane Database of Systematic Reviews* 8 (2019).
- XX. Lee, Seung Yeol, et al. "Incidence of deep vein thrombosis after major lower limb orthopedic surgery: analysis of a nationwide claim registry." *Yonsei medical journal* 56.1 (2015): 139-145.
- XXI. Kory, Pierre D., et al. "Accuracy of ultrasonography performed by critical care physicians for the diagnosis of DVT." *Chest* 139.3 (2011): 538-542.
- XXII. Broen, Kelly, Brian Scholtes, and Renée Vossen. "Predicting the need for further thrombosis diagnostics in suspected DVT is increased by using age adjusted D-dimer values." *Thrombosis research* 145 (2016): 107-108.
- XXIII. Tamura, Kiyoshi, and Hideki Nakahara. "MR venography for the assessment of deep vein thrombosis in lower extremities with varicose veins." *Annals of vascular Diseases* 7.4 (2014): 399-403.
- XXIV. Ho, Vincent B., et al. "ACR Appropriateness Criteria® on suspected lower extremity deep vein thrombosis." *Journal of the American College of Radiology* 8.6 (2011): 383-387.
- XXV. KAMIDA, CURTIS B., et al. "Lower extremity ascending and descending phlebography." *Handbook of Venous Disorders: Guidelines of the American Venous Forum Third Edition*. CRC Press, 2008.
- XXVI. Pieri, A., et al. "Filtres caves temporaires: notre expérience analyse préliminaire de 24 cas." *Phlébologie* 46.3 (1993): 457-466.
- XXVII. Houshmand, Sina, et al. "The role of molecular imaging in diagnosis of deep vein thrombosis."

The Role of Color Doppler Ultrasonography in the Prevention of Thromboembolic Disease after Total Hip Replacement

American journal of nuclear medicine and molecular imaging 4.5 (2014): 406.

- XXVIII. Eu, Peter. "An Update on the Detection of Deep Vein Thrombosis."
- XXIX. Kelly, J., et al. "Screening for subclinical deep-vein thrombosis." *Qjm* 94.10 (2001): 511-519.
- XXX. Kahn, Susan R., et al. "A randomized management study of impedance plethysmography vs. contrast venography in patients with a first episode of clinically suspected deep vein thrombosis." *Thrombosis research* 102.1 (2001): 15-24.
- XXXI. Locker, Thomas, et al. "Meta-analysis of plethysmography and rheography in the diagnosis of deep vein thrombosis." *Emergency medicine journal* 23.8 (2006): 630-635.
- XXXII. Tortoledo, Francisco, Leonardo Izaguirre, and María Alejandra Tortoledo. "Experiences and controversies related to the endovascular treatment of renovascular hypertension." *International Congress Series*. Vol. 1237. Elsevier, 2002.
- XXXIII. Shahzad, Ghazala, et al. "Diagnostic Accuracy of Color Doppler Ultrasonography among Patients Having Deep Vein Thrombosis by Taking Venography as Gold Standard." *Journal of Pharmaceutical Research International* (2020): 1-5.
- XXXIV. Wakefield, Thomas W., and Lazar J. Greenfield. "Diagnostic approaches and surgical treatment of deep venous thrombosis and pulmonary embolism." *Hematology/Oncology Clinics* 7.6 (1993): 1251-1267.
- XXXV. Needleman, Laurence, et al. "Ultrasound for lower extremity deep venous thrombosis: multidisciplinary recommendations from the Society of Radiologists in Ultrasound Consensus Conference." *Circulation* 137.14 (2018): 1505-1515.
- XXXVI. Planes, A., and N. Vochelle. "Anticoagulants and orthopedic surgery." *Anticoagulation*. Springer, New York, NY, 1994. 391-413.
- XXXVII. Streiff, M. B., Agnelli, G., Connors, J. M., Crowther, M., Eichinger, S., Lopes, R., McBane, R. D., Moll, S., & Ansell, J. (2016). Guidance for the treatment of deep vein thrombosis and pulmonary embolism. *Journal of thrombosis and thrombolysis*, 41(1), 32–67. <https://doi.org/10.1007/s11239-015-1317-0>
- XXXVIII. Paydar, S., Sabetian, G., Khalili, H., Fallahi, J., Tahami, M., Ziaian, B., Abbasi, H. R., Bolandparvaz, S., Ghaffarpasand, F., & Ghahramani, Z. (2016). Management of Deep Vein Thrombosis (DVT) Prophylaxis in Trauma Patients. *Bulletin of emergency and trauma*, 4(1), 1–7.
- XXXIX. Kakkos, S. K., Caprini, J. A., Geroulakos, G., Nicolaidis, A. N., Stansby, G., Reddy, D. J., & Ntouvas, I. (2016). Combined intermittent pneumatic leg compression and pharmacological prophylaxis for prevention of venous thromboembolism. *The Cochrane database of systematic reviews*, 9(9), CD005258. <https://doi.org/10.1002/14651858.CD005258.pub3>
- XL. Lippi, G., Favaloro, E. J., & Cervellin, G. (2011, April). Prevention of venous thromboembolism: focus on mechanical prophylaxis. In *Seminars in thrombosis and hemostasis* (Vol. 37, No. 03, pp. 237-251). © Thieme Medical Publishers.
- XLI. Shackford, S. R., Davis, J. W., Hollingsworth-Fridlund, P., Brewer, N. S., Hoyt, D. B., & Mackersie, R. C. (1990). Venous thromboembolism in patients with major trauma. *American journal of surgery*, 159(4), 365–369. [https://doi.org/10.1016/s0002-9610\(05\)81272-3](https://doi.org/10.1016/s0002-9610(05)81272-3)
- XLII. Capper, C. (1999). External pneumatic compression therapy for DVT prophylaxis. *British Journal of Theatre Nursing*, 9(3), 109.
- XLIII. Turnbull B. (2007). Prevention of DVT after orthopaedic surgery: the A-V Impulse System. *British journal of nursing* (Mark Allen Publishing), 16(10), 612–615. <https://doi.org/10.12968/bjon.2007.16.10.23509>
- XLIV. Do, E. J., Lenzini, P., Eby, C. S., Bass, A. R., Mcmillin, G. A., Stevens, S. M., . . . Gage, B. F. (2012). Genetics informatics trial (GIFT) of warfarin to prevent deep vein thrombosis (DVT): Rationale and study design. *The Pharmacogenomics Journal*, 12(5), 417-24. doi: <https://doi.org/10.1038/tpj.2011.18>
- XLV. Tadros, R., & Shakib, S. (2010). Warfarin: Indications, risks and drug interactions. *Australian family physician*, 39(7), 476-479.
- XLVI. Wadhera, R. K., Russell, C. E., & Piazza, G. (2014). Warfarin versus novel oral anticoagulants: how to choose? *Circulation*, 130(22), e191-e193.
- XLVII. Leyvraz, P. F., Bachmann, F., Hoek, J., Büller, H. R., Postel, M., Samama, M., & Vandenberg, M. D. (1991). Prevention of deep vein thrombosis after hip replacement: randomised comparison between unfractionated heparin and low molecular weight heparin. *British Medical Journal*, 303(6802), 543-548.
- XLVIII. Harenberg J. (2003). Thromboserapie mit niedermolekularem HeparinVergleich von körperrgewichtsadjustierter mit fixer Dosierung [Treatment of thrombosis with low-molecular-weight heparin. Comparison of body weight-adjusted and fixed dosage]. *Medizinische Klinik* (Munich, Germany: 1983), 98(9), 493–498. <https://doi.org/10.1007/s00063-003-1290-9>

The Role of Color Doppler Ultrasonography in the Prevention of Thromboembolic Disease after Total Hip Replacement

- XLIX. Leyvraz, P. F., M.D., Richard, J., M.D., Bachmann, F., M.D., van Melle, G., PhD, Treyvaud, J., M.D., Livio, J., M.D., & Candardjis, G., M.D. (1983). Adjusted versus fixed-dose subcutaneous heparin in the prevention of deep-vein thrombosis after total hip replacement. *The New England Journal of Medicine*, 309(16), 954-958.
- L. Horbach, T., Wolf, H., Michaells, H. C., Wagner, W., Hoffmann, A., Schmidt, A., & Beck, H. (1996). A fixed-dose combination of low molecular weight heparin with dihydroergotamine versus adjusted-dose unfractionated heparin in the prevention of deep-vein thrombosis after total hip replacement. *Thrombosis and haemostasis*, 75(02), 246-250.
- L.I. Sobieraj, D. M., Coleman, C. I., Tongbram, V., Chen, W., Colby, J., Lee, S., ... & White, C. M. (2012). Comparative effectiveness of low-molecular-weight heparins versus other anticoagulants in major orthopedic surgery: a systematic review and meta-analysis. *Pharmacotherapy: The Journal of Human Pharmacology and Drug Therapy*, 32(9), 799-808.
- LII. Levine, M., Gent, M., Hirsh, J., Leclerc, J., Anderson, D., Weitz, J., ... & Willan, A. (1996). A comparison of low-molecular-weight heparin administered primarily at home with unfractionated heparin administered in the hospital for proximal deep-vein thrombosis. *New England Journal of Medicine*, 334(11), 677-681.
- LIII. Turhan, S., Karaarslan, K., & Abud, B. (2021). The usage and outcomes of dextran in the treatment of acute deep venous thrombosis. *Vascular*, , 17085381211067039.
- LIV. Collaborative overview of randomised trials of antiplatelet therapy--III: Reduction in venous thrombosis and pulmonary embolism by antiplatelet prophylaxis among surgical and medical patients. antiplatelet trialists' collaboration. (1994). *BMJ. British Medical Journal (Clinical Research Ed.)*, 308(6923), 235.
- LV. Khai, T., Mary-Doug, W., & Melissa, S. (2020). Acetylsalicylic Acid for Venous Thromboembolism Prophylaxis in Total Hip or Knee Replacement: A Review of Clinical Effectiveness and Guidelines. Canadian Agency for Drugs and Technologies in Health.
- LVI. Imperiale, T. F., & Speroff, T. (1994). A meta-analysis of methods to prevent venous thromboembolism following total hip replacement. *Jama*, 271(22), 1780-1785.
- LVII. Kassai, B., Boissel, J. P., Cucherat, M., Sonie, S., Shah, N. R., & Leizorovicz, A. (2004). A systematic review of the accuracy of ultrasound in the diagnosis of deep venous thrombosis in asymptomatic patients. *Thrombosis and haemostasis*, 91(04), 655-666.
- LVIII. Davidson, B. L., Elliott, C. G., Lensing, A. W., & RD Heparin Arthroplasty Group*. (1992). Low accuracy of color Doppler ultrasound in the detection of proximal leg vein thrombosis in asymptomatic high-risk patients. *Annals of internal medicine*, 117(9), 735-738.
- LIX. Grady-Benson, J. C., Oishi, C. S., Hanson, P. B., Colwell Jr, C. W., Otis, S. M., & Walker, R. H. (1994). Postoperative surveillance for deep venous thrombosis with duplex ultrasonography after total knee arthroplasty. *The Journal of Bone and Joint Surgery. American Volume*, 76(11), 1649-1657.
- LX. Marcucci M., Di Muria Gv, Di Bella L., Lazzara D. (1995) Validity of venous color Doppler in the prevention of thromboembolic disease after total hip replacement. Work in progress of publication on Acts VIII National Congress SPIGC 1995.
- LXI. EINSTEIN Investigators, Bauersachs, R., Berkowitz, S. D., Brenner, B., Buller, H. R., Decousus, H., Gallus, A. S., Lensing, A. W., Misselwitz, F., Prins, M. H., Raskob, G. E., Segers, A., Verhamme, P., Wells, P., Agnelli, G., Bounameaux, H., Cohen, A., Davidson, B. L., Piovella, F., & Schellong, S. (2010). Oral rivaroxaban for symptomatic venous thromboembolism. *The New England journal of medicine*, 363(26), 2499-2510. <https://doi.org/10.1056/NEJMoa1007903>
- LXII. Lyon, C., Mathern, S., Devitt, J., & DeSanto, K. (2017). Rivaroxaban vs. Warfarin for Treatment of DVT and PE. *American family physician*, 96(8), 532-533.